

Patient: ani mihailova

Disease:

ID:

DOB (age): 18/12/2007 (6) Gender: F

Exam Date: 30/05/2014

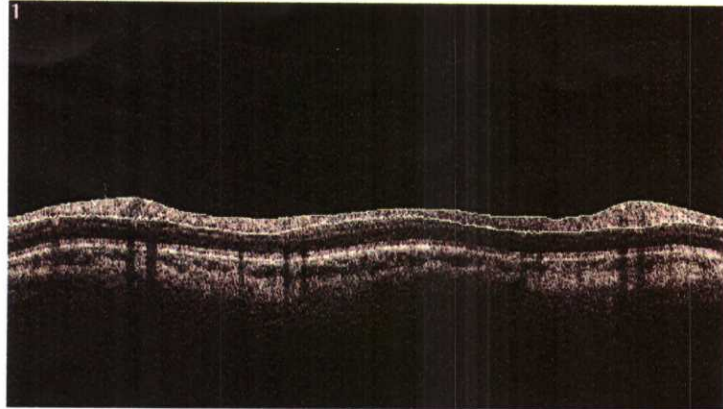
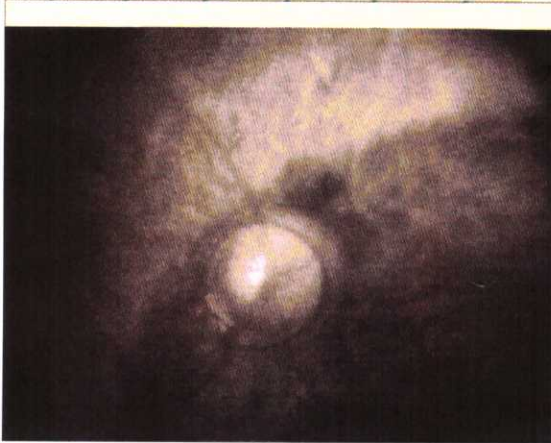Physician:

Algorithm Version: A4, 0, 0, 143

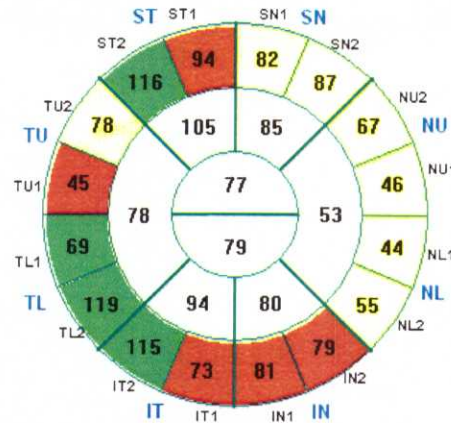
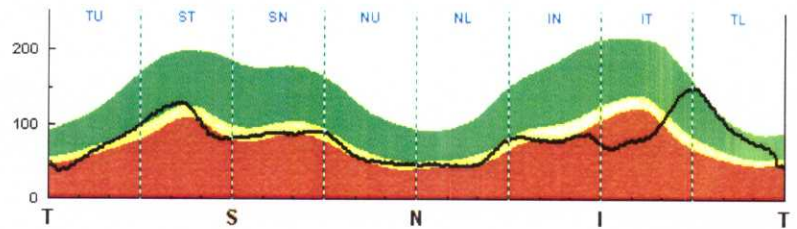
OD

RNFL3.45 SSI= 54.0

3.45mm Scan Diameter



Section	Thickness (µm)
Std Dev Of RNFL = 4.56	
Overall RNFL = 78	
S. Hemisphere = 77	
I. Hemisphere = 79	
TEMPO	78
TL	94
TU	61
SUPERIOR	95
ST	105
SN	85
NASAL	53
NU	57
NL	50
INFERIOR	87
IN	80
IT	94



p>5% Within Normal
p<5% Borderline
p<1% Outside Normal

Diagnosis:

Report Date: Friday May 30 15:04:31 2014

Report Date: Friday May 30 15:04:48 2014

Software Version #4, 0, 0, 143

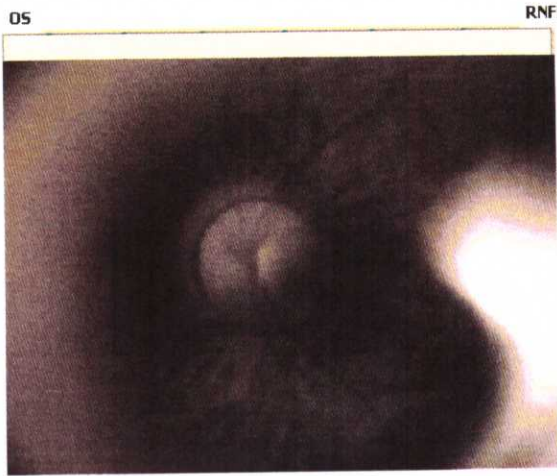
Comments:

Signature:

Patient: ani mihailova
Disease:
ID:

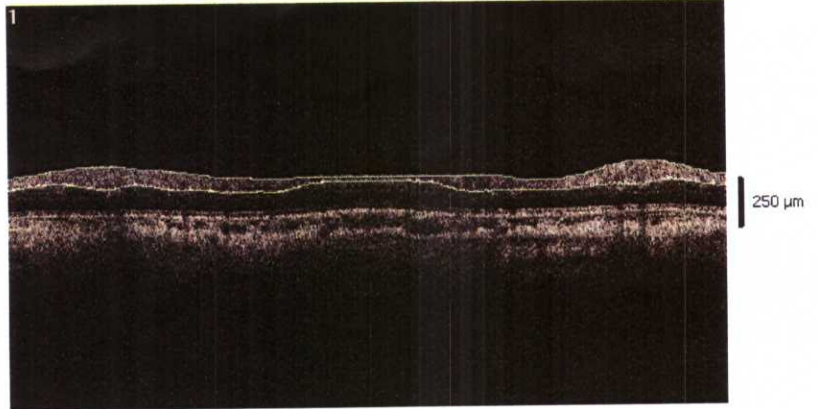
DOB (age): 18/12/2007 (6) Gender: F

Exam Date: 30/05/2014
Physician:
Algorithm Version: A4, 0, 0, 143

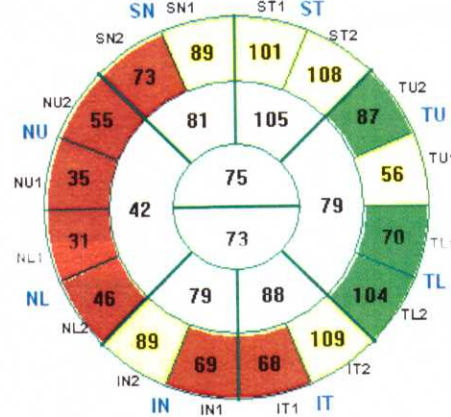
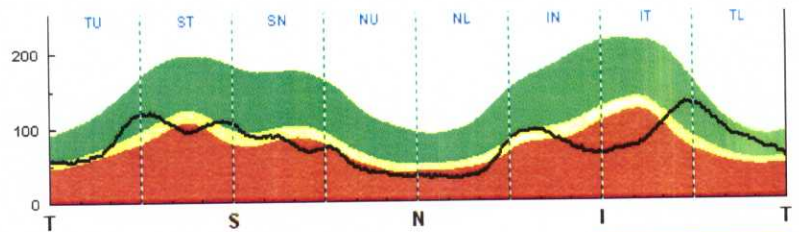


RNFL3.45 SSI= 45.6

3.45mm Scan Diameter



Section	Thickness (µm)
Std Dev OF RNFL = 3.59	
Overall RNFL = 74	
S. Hemisphere = 75	
I. Hemisphere = 73	
TEMPO	79
TL	87
TU	72
SUPERIOR	93
ST	105
SN	81
NASAL	42
NU	45
NL	38
INFERIOR	84
IN	79
IT	88



Diagnosis:

Report Date: Friday May 30 14:58:24 2014

Report Date: Friday May 30 14:59:20 2014

Software Version #4, 0, 0, 143

Comments:

Signature:

The OCT Experts

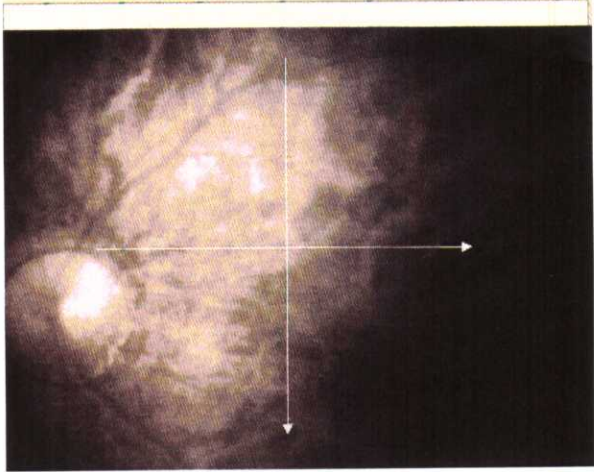
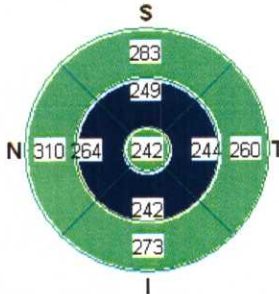


Patient: ani mihailova
Disease:
ID:

DOB (age): 18/12/2007 (6) Gender: F

Exam Date: 30/05/2014
Physician:
Algorithm Version: A4, 0, 0, 143

OS EMM5 SSI= 54.5

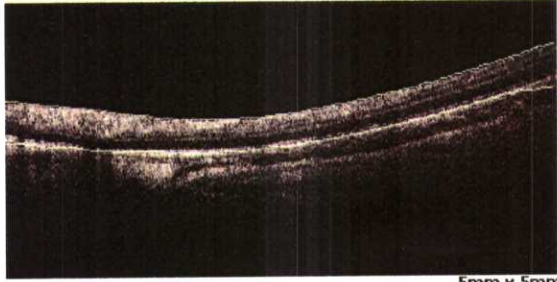



Optional Display

Map Diameters

Fovea: 1.00 mm
Parafovea: 3.00 mm
Perifovea: 5.00 mm

Significance Legend:
 p > 99% (Red)
 p > 95% (Orange)
 p > 5% (Yellow)
 p > 1% (Green)
 p < 1% (Blue)



Threshold: 0
Volume: 6.78 mm

Show Lines
Thickness: 233 μm (0.00, 0.00) mm

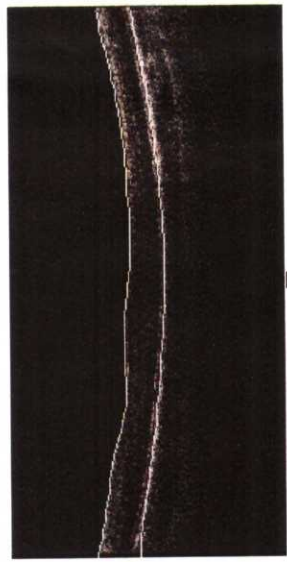
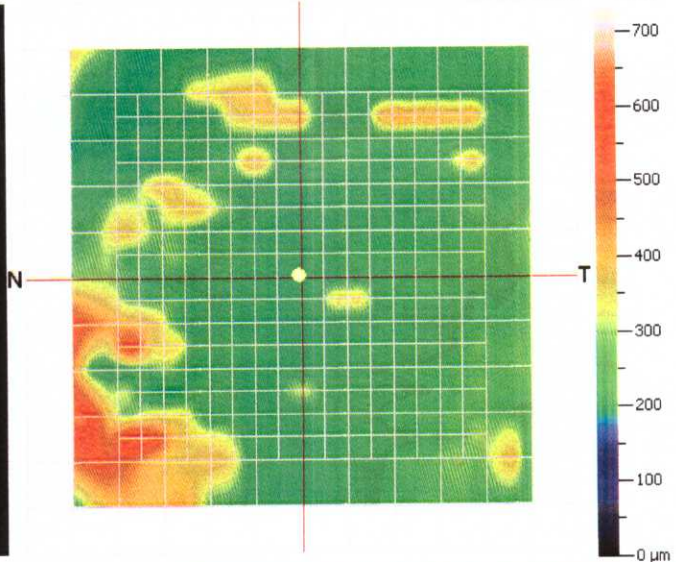
Section	Thick(μm)	Vol(mm)
Fovea	242	0.190
ParaFovea	250	1.570
S. Hemisphere	251	0.787
I. Hemisphere	249	0.782
Tempo	244	0.384
Superior	249	0.391
Nasal	264	0.414
Inferior	242	0.381
Perifovea	282	3.538
S. Hemisphere	276	1.732
I. Hemisphere	287	1.806
Tempo	260	0.815
Superior	283	0.888
Nasal	310	0.975
Inferior	273	0.859

Vol within: 0.190(1mm) 1.760(3mm) 5.298(6mm)

Thickness: Full Retinal Inner Retinal Outer Retinal
 Elevation: ILM RPE
 Significance: Full Retinal RPE

Show Boundary Curves

Diagnosis:

Report Date: Friday May 30 15:14:26 2014

Report Date: Friday May 30 15:14:36 2014

Software Version #4, 0, 0, 143

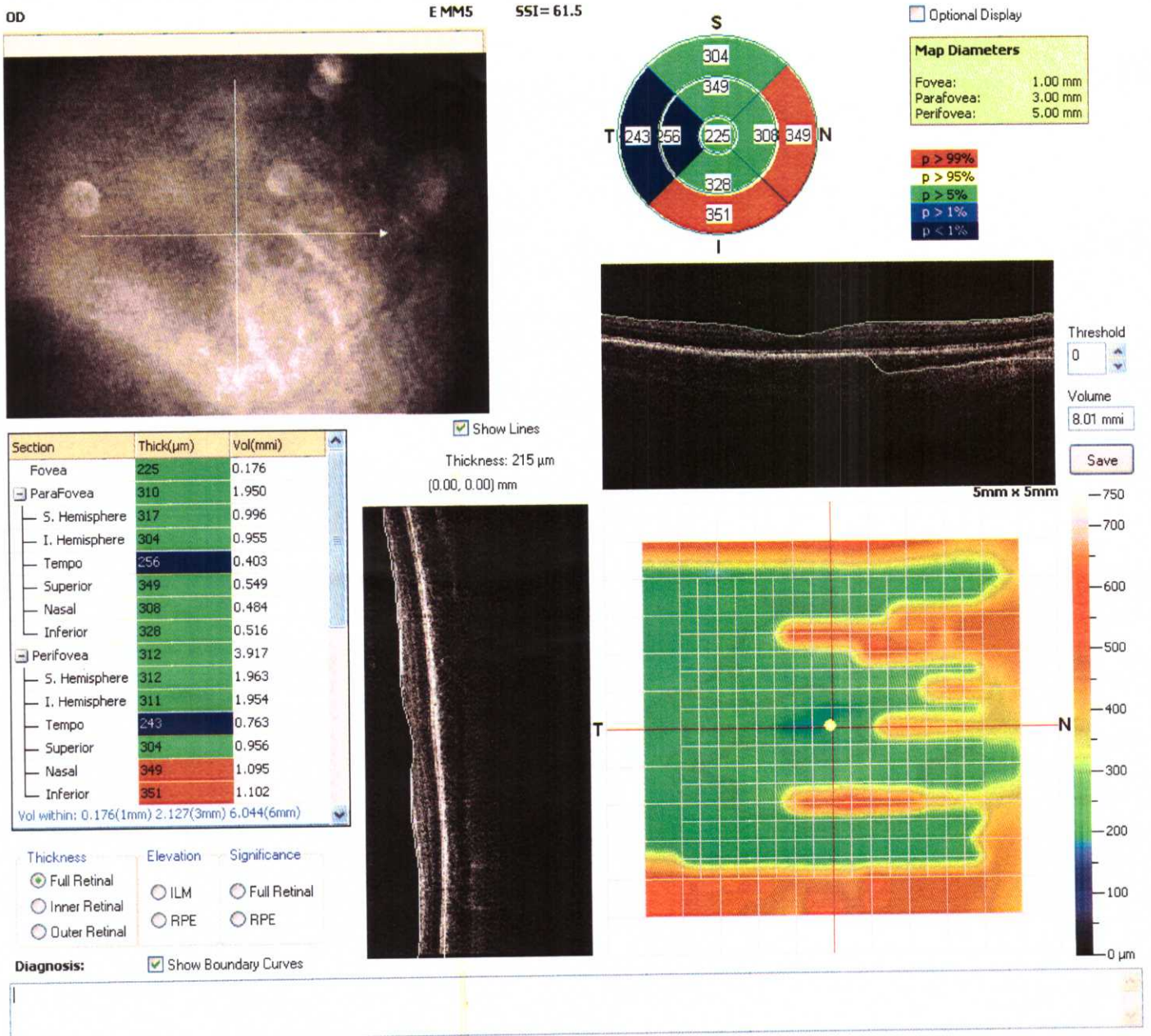
Comments:

Signature:

Patient: ani mihailova
Disease:
ID:

DOB (age): 18/12/2007 (6) Gender: F

Exam Date: 30/05/2014
Physician:
Algorithm Version: A4, 0, 0, 143



Report Date: Friday May 30 15:14:15 2014

Report Date: Friday May 30 15:14:24 2014

Software Version #4, 0, 0, 143

Comments:

Signature:

The OCT Experts

